

FORUM IMPLANTOLOGICUM

IN FOCUS

Selection of Implants in Daily Practice

ASK THE EXPERTS

Peri-implantitis: Decision Criteria for Implant Removal

TIPS

Virtual Presentations: How to Connect with an Online Audience

Implant Shapes and Macro-designs: Advantages and Disadvantages

Jeffrey Ganeles, Frederic J. Norkin, Debora R. Dias, Philip Fava, Robert A. Levine, Liliana Aranguren

ABSTRACT

Every time a dentist places an implant in a patient, a series of decisions are made regarding implant selection. Implant macro- and micro-design are dictated by manufacturers. There are patient-related metrics like anatomical evaluation, restorative intention, time to loading, restorative space and other factors that are important. Dentist-related criteria like brand preference, cost, personal experience, education, exposure to marketing and available inventory also influence the selection.

Obvious differences between implants include their shape, thread pattern, transmucosal design and prosthetic connection, which together comprise their macro-design. Each of these elements can be engineered or manufactured to impact different clinical performance features of the implants such as primary stability, crestal bone stability, implant fracture toughness, abutment selection, ability to implement digital workflow, augmentation requirements and esthetics. Texture, composition and surface treatment also alter implant options but are considered micro-design features not included in this review.

Categorizing and analyzing design features of implants should help clinicians prioritize and select design features that enhance or facilitate treatment decisions for their patients in each clinical situation. Clinicians should be aware of options and, when possible, should deliberately select the most appropriate implant for each specific indication based on these criteria in order to optimize efficiencies and outcomes. It should clearly be recognized that implant selection alone will neither ensure success nor trigger failure in the absence of other surgical and restorative considerations. This paper will review the macro-design features and suggest clinical guidelines for choosing appropriate implants.

Keywords: Implant macro-design, dental implants, implant thread, implant design

INTRODUCTION

Dental implants are a predictable treatment option to replace missing teeth from a functional and esthetic perspective (Jung et al. 2012; Jung et al. 2018). The dental implant market has grown exponentially in the last decades. New brands, different materials and designs, each with a goal of long-term success, are available. Osseosource.com (www.osseosource.com) tracks hundreds of dental implant manufacturers with over 2,000 implant designs manufactured worldwide (Jokstad & Ganeles 2018).

The process of osseointegration in implant dentistry requires implants to be sufficiently immobilized in bone for the complex cellular and cytokine mediated sequence of bone formation onto the implant surface to occur. The biomechanical events are well understood and can be influenced by many factors including implant design (Terheyden et al. 2012; Albrektsson et al. 1981). These devices are manufactured to optimize clinical success while focusing on increasing primary stability, crestal bone stability, optimizing clinical and esthetic outcomes and decreasing augmentation requirements. It should also be acknowledged that many of the different features incorporated into many implants may be marketing-related and business-oriented, rather than evidence-based.



Dr. Jeffrey Ganeles is a periodontist from Boca Raton, FL. Currently, he is an Associate Professor at Nova Southeastern University, in Ft. Lauderdale, Florida and Boston University, Boston MA. He is a Diplomate of the American Board of Periodontology, a Fellow of the American College of Dentists, a Fellow and Member of the Board of Directors of the AO and a Fellow of the ITI.



Dr. Frederic J. Norkin maintains a full-time private practice in Boca Raton, Florida at the South Florida Center for Periodontics & Implant Dentistry. He is a Diplomate of the American Board of Periodontology and a Fellow of the ITI.



Dr. Debora R. Dias completed a specialty program in Periodontics in 2018 and a Master's Degree in 2021 from the State University of Maringa, Brazil. She is currently a Member of the ITI, Osteology Foundation National Group and the Brazilian Society of Periodontology (SOBRAPE).



Dr. Philip Fava is a periodontist practicing at the Pennsylvania Center for Dental Implants & Periodontics in Philadelphia, PA. He is a Diplomate of the American Board of Periodontology and a Fellow of the ITI.



Dr. Robert A. Levine maintains a private practice in Philadelphia at the Pennsylvania Center for Dental Implants and Periodontics. He is Clinical Professor at Temple University Kornberg School of Dentistry and Clinical Associate Professor at the University of North Carolina at Chapel Hill. Dr. Levine is a Diplomate of the American Board of Periodontology and a Fellow of the ITI.



Dr. Liliana Aranguren is a periodontist at the South Florida Center for Periodontics & Implant Dentistry in Boca Raton, FL. She completed residencies at the University of Connecticut in Advanced Education in General Dentistry in 2013, Certificate in Periodontics and Master's in Dental Sciences in 2016. She is a Diplomate of the American Board of Periodontology, a member of the AO and a Fellow of the ITI.

Different implant shapes and designs have been manufactured and investigated in the literature. Variations between designs include the abutment connection method, platform-switching versus matched diameter abutments, bone level versus tissue level, tapered versus cylindrical designs, thread patterns and others (Abuhussein et al. 2010; Atieh et al. 2018; Jung et al. 2018). However, the implant selection for each case incorporates more than objective implant-related criteria. Patient- or site-related factors such as timing of implant placement and loading protocol, esthetic or non-esthetic zone, hard and soft tissue anatomy, restorative space, availability of restorative components and single or multiple-tooth rehabilitation impact the selection of specific implant designs. The surgeon's experience is an important determinant as well.

Clinicians should be aware of the favorable and unfavorable features of each implant design for case selection in order to increase treatment success. This article focuses on metallic implant macro-design features.

TAPERED VS. PARALLEL-WALLED

Planning implant restorations often requires navigating challenging anatomy. Implant placement may be limited by adjacent vital structures such as tooth roots, the mandibular canal and mental foramen, the lingual artery and the maxillary sinuses. Further, naturally occurring anatomical variations such as buccal or lingual concavities in the alveolus may limit available bone for implant placement. Bone may be further limited by alveolar resorption subsequent to periodontal disease, periapical pathology from pulpal necrosis and subsequent alveolar destruction or alveolar resorption associated with tooth loss. Implant site limitations due to adjacent anatomic structures emphasize the need for appropriate presurgical implant planning. Implants have the best long-term survival when there is at least 1.5–2.0 mm of vital bone surrounding the implant circumferentially, ensuring long-term hard and soft tissue maintenance (Monje et al. 2019).

Several options are available for maximizing available alveolar bone while minimizing the need for grafting as well as avoiding damage to local structures. Among them, clinicians have the option of placing cylindrical versus tapered implants to avoid colliding with vital structures or adjacent implants. One of the more fundamental methods for categorizing implant design is the intra-bony shape of the implant outer walls as being parallel (also called cylindrical) or tapered. It is estimated that there are more than 500 implant manufacturers making about 4,000 implant brands with varying designs. There is no specific tracking site or organizational body registering these products. One of the most informative sites is Osseosource.com, which is an independent website focused on tracking dental implant products. It lists 1,990 different implant brands and models. Of these, 1,082 are cylindrical (parallel-walled) and 908 are tapered. For clarity, Jokstad & Ganeles (2018) suggested that “A tapered dental implant, often named ‘conical’ [...] is identifiable by displaying some convergence of the implant outer walls toward the apex of the endosseous part of the implant body, that is, the portion of the implant body intended to be positioned within the bone.”

While most of the original dental implants manufactured were cylindrical, there has been a trend in the last decades towards more tapered designs (Fig. 1). Tapered designs may offer higher insertion torque values and resonance frequency (RFA) values in standard bony sites compared to similarly sized cylindrical implants under standard drilling procedures (Toyoshima et al. 2015; Atieh et al. 2018). In theory, this is an attractive property of these implants for problematic sites with low density bone. Martinez et al. (2001) proposed that conical geometry can provide implants in poor quality bone better stability to achieve more reliable osseointegration. The literature does not directly support this theory and no advantage for cylindrical or tapered implant design has been substantiated regarding implant success with conventional loading protocols (Jokstad & Ganeles 2018; Waechter et al. 2017).

Early and immediate loading protocols require high insertion torque and RFA values to achieve successful osseointegration (Esposito et al. 2007, Gallucci et al. 2018). The finding that tapered implants provide

these higher values suggests that they are generally better suited for this clinical indication compared to cylindrical implants (Gehrke et al. 2015). It should be recognized that successful early and immediate loading has been shown with both cylindrical and tapered implants indicating that while tapered implants may provide advantages in this circumstance, they are not essential for success (Nicolau et al. 2013; Kim et al. 2013). Two recent systematic reviews (Atieh et al. 2018; Jokstad & Ganeles 2018) pointed to other factors with a major influence, such as bone quality and quantity, and the osteotomy preparation may also play a role. Implant surface characteristics also influence success in early and immediate loading (El Kholy et al. 2019).

Other more pragmatic factors may be relevant for deciding between a tapered and a cylindrical implant. In most patients and for most teeth, the clinical crowns are wider mesio-distally and bucco-lingually than at the apices. Most maxillas and mandibles converge apically where an arc drawn through the coronal aspects of teeth has a greater circumference than an arc drawn through the apices. This generally means that there is a greater volume of bone coronally compared to apically. As a result, a cylindrical implant placed into a tapering ridge has a higher chance of perforating a buccal plate apically compared to a tapered implant of the same length and coronal dimension (Figs 2 and 3).

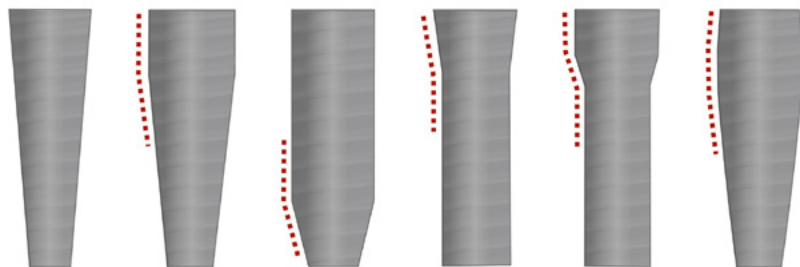


Fig. 1: Illustration of different tapered implant designs

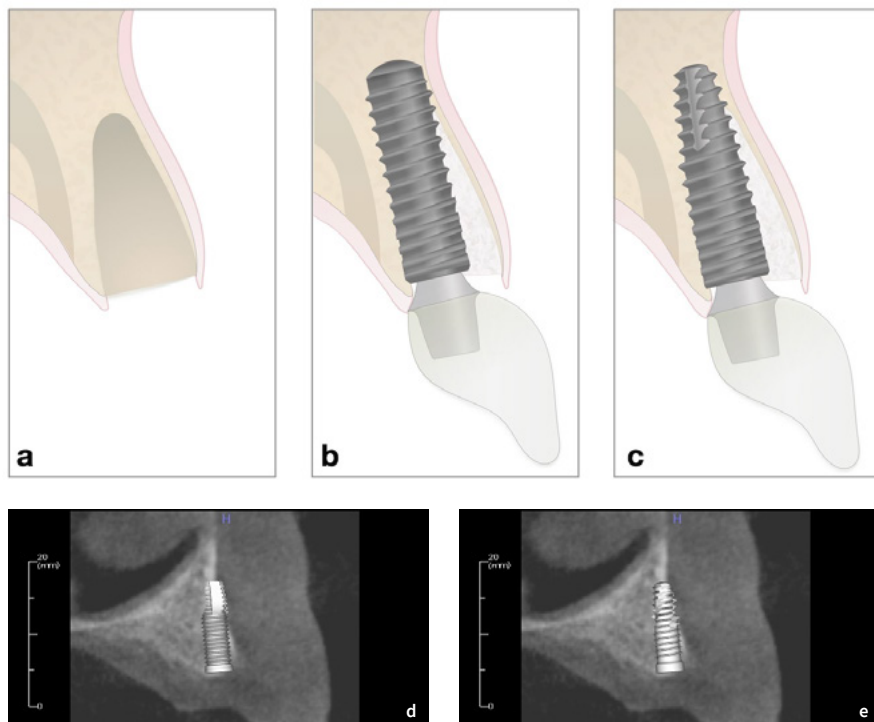


Fig. 2: Increased apical dehiscence for cylindrical implant compared to tapered implant in the same position in the same ridge. a: Socket with thin buccal plate. b: Cylindrical implant perforating the buccal plate apically c: Tapered implant within the alveolar contours d: Radiograph simulating cylindrical implant with apical perforation e: Radiograph simulating minimal perforation with tapered implant

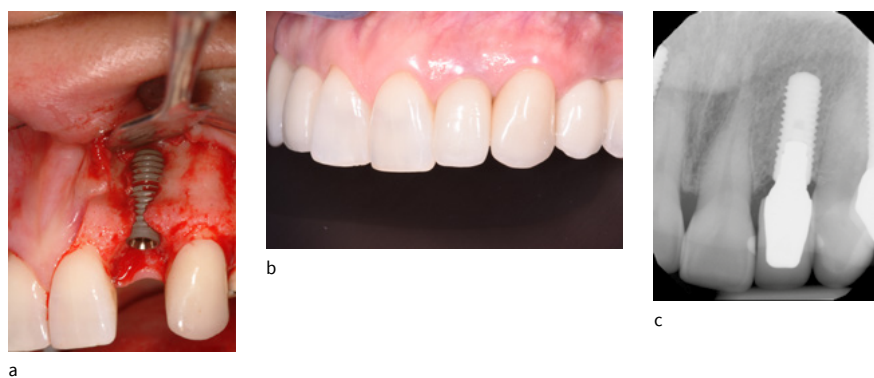

Fig. 3: Cylindrical implant caused need for additional grafting. A similarly sized tapered implant was not available at the time of surgery. 10-year result shows that despite this macro-design-induced challenge, excellent esthetic results and tissue stability were achieved. a: surgical placement with significant apical protrusion of the cylindrical implant. b: 10-year clinical result showing stable tissue contours. c: 10-year radiograph showing stable proximal bone levels

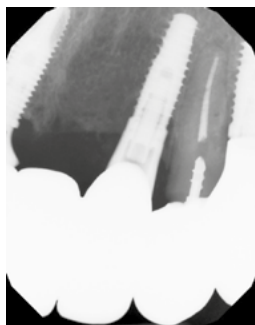


Fig. 4: Tapered implant is less likely to damage adjacent roots apically, when placed in close proximity. 6-year post-treatment

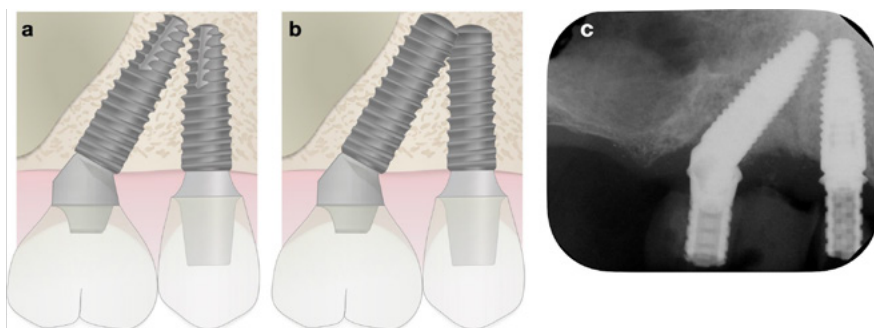


Fig. 5: Inter-implant spacing with tilted implants is more difficult with cylindrical implants compared to tapered implants and can result in apical collisions unless shorter implants are used, which may reduce primary stability. a: Close approximation of the apices of tapered implants. b: collision of the apices of cylindrical implants of the same size. c: Example of placement using guided surgery with apices in close approximation




Fig. 6: Tapered vs cylindrical initial bone contact depth

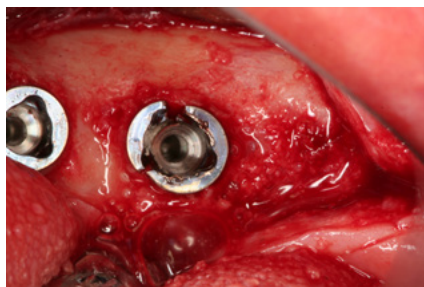


Fig. 7: Fractured tapered implant caused by under-drilling the osteotomy and/or over-seating the implant in dense bone

In tight interdental spaces, tapered designs provide a greater safety margin when placing an implant near existing roots (Fig. 4). Similarly, when placing tilted implants in close proximity, using tapered implants permits maximum utilization of available bone volume, compared to cylindrical implants that would need to be shorter to avoid collision with each other (Fig. 5).

Tapered and cylindrical implants differ in the way they tighten into their respective osteotomies. Cylindrical implants engage the cortical plate and thread into position along a parallel chamber prepared by the drill. Assuming the osteotomy is slightly overextended (as most often occurs) this allows the surgeon flexibility to adjust implant height by rotating the implant deeper or shallower into the osteotomy without significantly changing insertion torque or RFI. Tapered implants are generally placed into conical preparations so that they fit more precisely into the osteotomy and are less depth-adjustable without losing stability (shallower placement) or compressing bone (deeper placement) (Fig. 6). Additionally, if excessive bone compression occurs, which happens primarily with tapered implants, delayed healing, bone loss, carrier fracture or implant fracture can occur (Fig. 7) (Tabasum et al. 2011, Jimbo et al. 2014; Barone et al. 2016).

An incidental benefit of deeper initial seating within the osteotomy for tapered implants is that they lead to more accurate placement during static guided surgery compared to cylindrical implants (El Kholy et al. 2019). This is true in all dimensions of measurement including bodily position and angular deviations. The authors speculated that the implant macro-design may have an influence on the accuracy of the procedure.

THREAD PATTERN

Implant threads have several functions in implant dentistry. They guide the implant into position and provide primary stability, initially connecting the implant to bone surrounding the osteotomy. Combined with the implant shape and osteotomy parameters, they influence the initial bony microenvironment by transmitting force, tension and compression to crestal and medullary bone. They may create microchambers (hollow spaces that fill with blood) within the alve-

olar housing to encourage bone formation (Gehrke et al. 2014). Once implants are fully integrated, they can assist in maintaining homeostatic conditions by directing occlusal forces into the surrounding bone (Abuhussein et al. 2010).

Implant thread patterns can be described in mechanical engineering terminology applied to the description of screws. This includes thread geometry, face angle, thread pitch, thread depth and thread helix (Fig. 8) (Geng et al. 2004). A detailed explanation of thread design can be found in Abuhussein et al. (2010).

Aggressive thread patterns (deep thread depth, wide thread pitch or face, possibly combined with a tapered body) have also been investigated for increasing primary stability. Even with limited evidence to suggest long-term effectiveness, these features can be valuable to immediate or early loading protocols because they increase the bone-to-implant contact due to the larger surface area (Gehrke et al. 2015; McCullough & Klokkevold 2017). Abuhussein et al. (2010) reported similar findings. The authors observed that good bone quality, long or wide diameter implants, more threads, smaller pitches, deep threads and decreased thread helix angle should be used to increase primary stability. These design strategies are associated with increasing the implant surface in contact with the bone.

Similarly, if implants are placed in conditions with little bone, such as in immediate or early implant placement, increasing the apical surface area of implants should logically improve the surgeon's ability to obtain primary stability and simultaneously graft around the implant. Figure 9 shows a clinical situation where early placement was planned approximately 6 weeks following tooth extraction, which allowed soft tissue healing, but little-to-no bony healing in the socket. This treatment protocol is well documented to provide stable long-term esthetic results but requires that the implant be placed with sufficient primary stability (Chappuis et al. 2018).

IMPLANT/ABUTMENT CONNECTIONS

Three different implant connections have been described in the literature with different biological and mechanical properties:

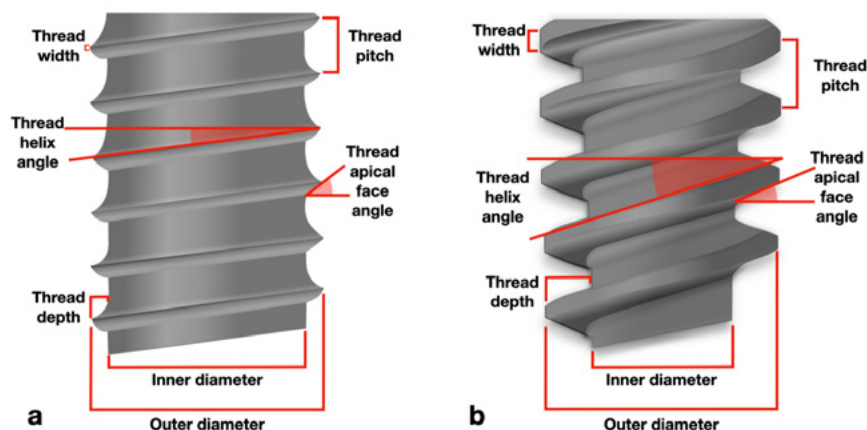


Fig. 8: Implant thread definitions. a: Reverse buttress screw design b: Spiral thread design

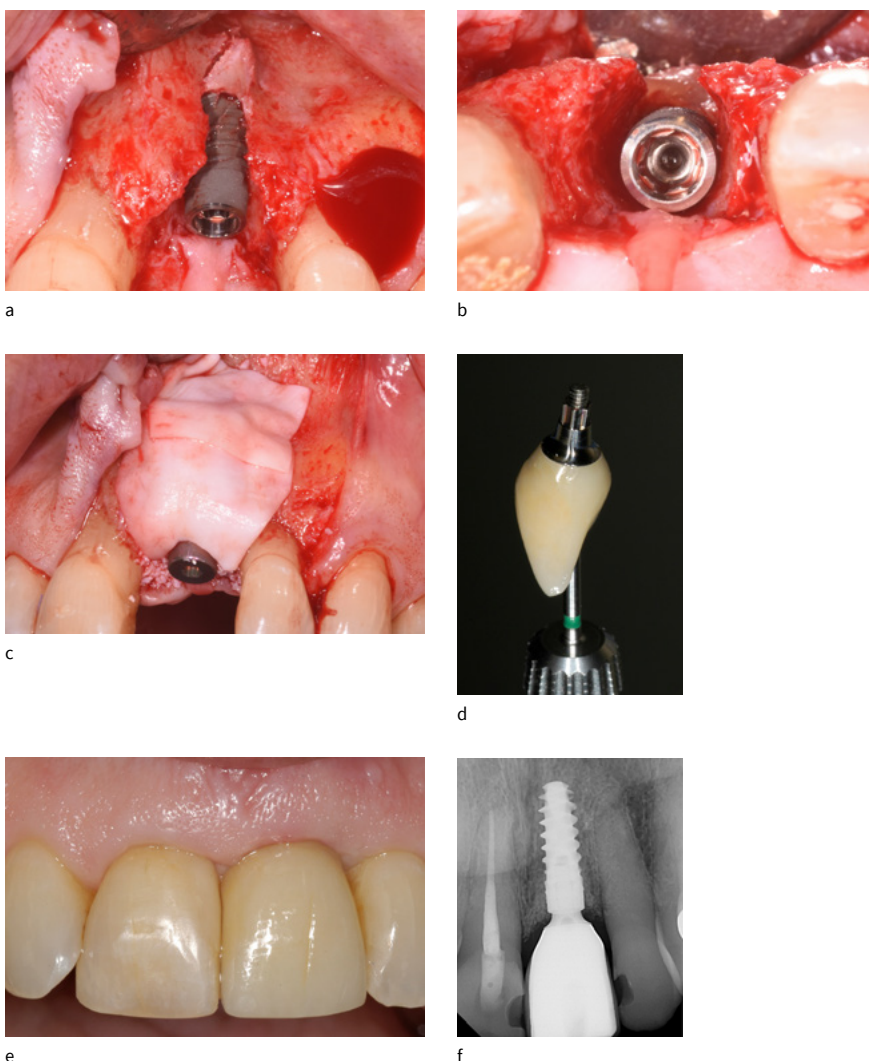


Fig. 9: Implant with deep apical threads used to optimize primary stability despite the lack of coronal-bone contact in this early (6-week post-extraction) placement with simultaneous augmentation. a: Surgical placement with apical stabilization. b: Occlusal view showing no coronal retention. c: Grafting. d: Final screw-retained crown. e: Final restoration in place. f: 1 year post-op radiograph

external, internal and conical. External connection usually presents a standard external hexagon (EH) on the implant platform where the abutment connects. Internal connections comprise a variety of internal morphologies including internal hexagon [IE], internal octagon and internal trilobe. These internal features are often created with a parallel or conical internal connection (Fig. 10) (Caricasulo et al. 2018).

External connections were the original design for osseointegrated implants introduced by Branemark as a method to deliver and torque the implant into the osteotomy. They have an external hexagon at the coronal portion connecting to the abutment (Fig. 11a). With this design the prosthetic screw receives more load than the prosthetic screw of an internal connection and is more likely to have screw loosening and biological complications. Because this connection relies heavily on the screw, the abutment shows more movement than abutments in an internal connection. This results in a larger micro-gap which becomes colonized by bacteria. These implants are susceptible to bone loss, especially when placed subcrestally (Koutouzis 2019). This makes this implant design less favorable for cantilevered restorations that are not splinted in a full arch.

Internal connections were developed to reduce these complications. The most common design is an internal hexagon, where a parallel-walled abutment is connected to an internal hexagon inside the implant, to avoid friction between the components (Fig. 11b) (Koutouzis 2019). This design results in less load transmission to the prosthetic screw, even when implant diameter decreases. This protects the bone at the implant shoulder from the micromotion of the abutment which theoretically aids in bone maintenance and decreases the frequency of screw loosening.

Conical internal connections were an evolution of design to reduce the micro-leakage caused by micro-gaps in the implant-abutment interface, as well as micromovements during loading. A tapered interface between implant and abutment provides a high degree of friction, resulting in a stable connection (Figs 11c–d) (Zipprich et al. 2018). Stability is important for abutment connections because the movement seen in the abutment level, regardless of

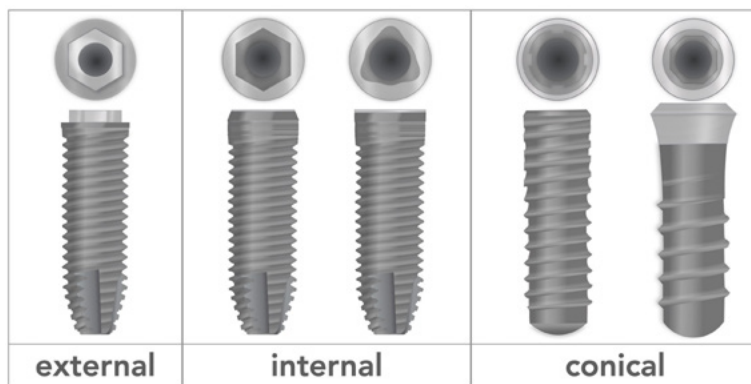


Fig. 10: Implant designs and connections

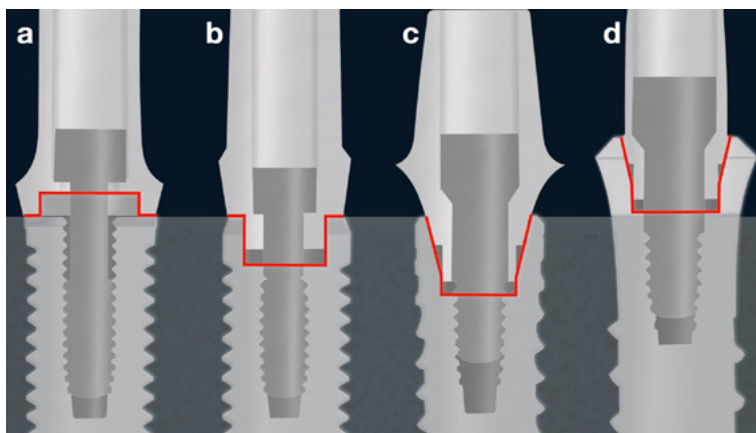


Fig. 11: Implant/abutment external (a), internal (b) and conical (c, d) connections. a, b, c: Bone level implants. d: Tissue level implant

size of micro-gap, influences the stability of crestal bone (Hermann et al. 2001a). A previous study showed less marginal bone loss when using conical internal connections (Gultekin et al. 2013). This connection also seems to better dissipate loading at implant/abutment interface, reducing the incidence of complications such as screw-loosening or fracture (Caricasulo et al. 2018).

In addition to the implant-abutment connection, the diameter of the abutment has been a subject of study in recent decades. Platform matching (PM) external hexagon implants and restorative abutments were used as the original design in implant dentistry. It is well known in the literature that following implant placement, bone resorption will occur to establish an appropriate biological width (Berglundh & Lindhe 1996; Hermann et al. 2001b). This crestal bone remodeling is called “saucerization” (Fig. 12), in which the marginal bone level is stabilized at 1.5–2 mm below the implant-abutment junction (Albrektson et al. 1986). The micro-gap between the implant and abutment becomes colonized by bacteria and, because of its proximity to the bone, can lead to bone loss (Figs 13a, c and e) (Hermann et al. 2001a; Hermann et al. 2001b; Koutouzis 2019).

The concept of platform switching (PS) was first introduced accidentally by Lazzara & Porter (2006) and seemed to preserve peri-implant marginal bone level in external hexagon implants. It is based on the theory that using an implant platform with a diameter larger than the corresponding abutment would provide a horizontal space for the biological width, reducing bone resorption vertically (Figs 13b, d and f). It would also shift the micro-gap and inflammation medially away from the bone and distribute the biomechanical stress toward the central axis of the implant (Maeda et al. 2007). There are various systematic reviews comparing PM and PS on peri-implant marginal bone level supporting this theory, with PS implants showing less marginal bone loss (MBL) (Annibali et al. 2012; Monje & Pommer 2015; Strietzel et al. 2015; Caricasulo et al. 2018). The combination of conical connection with platform switching is, according to most of the current literature, the most advantageous for biological and mechanical stability.

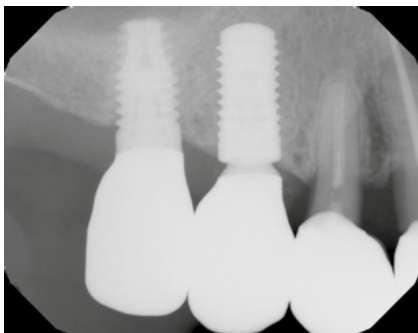

Fig. 12: 8-year-old implant with matching diameter implant and abutment shows 1-2-mm bone loss while adjacent 4-year-old platform-switched implant shows no bone loss

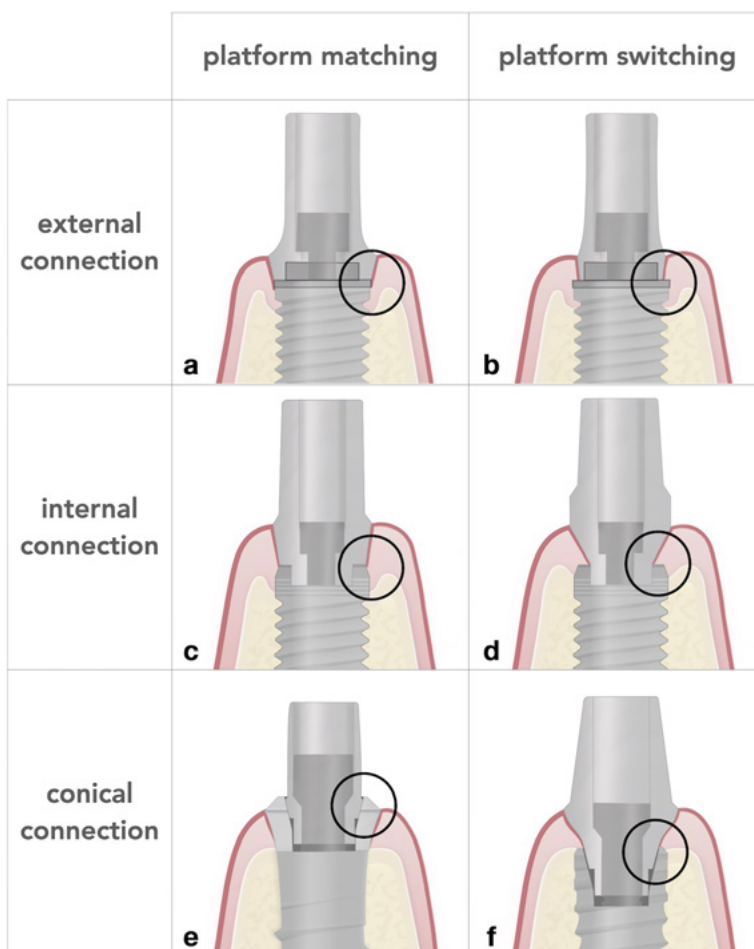


Fig. 13: Implant external (EC), internal (IC) and conical (CC) connections and platform matching (PM) or switch (PS) abutments. a: EC with a PM abutment, observe the bone resorption around the implant due to the proximity of the micro-gap/interface with the bone. b: using the same connection but with a PS abutment, observe the increased horizontal distance from the micro-gap, reducing the marginal bone loss. c: An internal parallel wall connection with a PM abutment, observe the reduced bone loss when compared to EH and PM. d: IC and PS, the horizontal shift of the micro-gap and more stable bone. e: CC with PM, but in this case, the tissue level implant shifts the micro-gap/interface vertically to the soft tissue, observe the minimal bone loss. f: CC with PS in a bone level implant, showing minimal bone alterations

When placing adjacent implants in the esthetic zone, the presence of the interproximal papilla is a major concern. Implant connections and platform sizes have a direct impact on these esthetic outcomes (Ramanauskaite et al. 2018). Tarnow et al. (2000) evaluated the effect of the inter-implant distance on the height of the inter-implant bone crest, by placing EH implants with PM. The authors reported that implants placed with an inter-implant distance ≤ 3 mm presented greater crestal bone loss (height) because the horizontal component of the saucerization process of each implant overlapped. And worse, with a reduction in height of the crestal bone, the height of the interproximal papilla was also reduced, resulting in “black triangles” (Figs 14a–c). Studies with PS implants have shown lower risk of interproximal bone loss and more predictable outcomes when placing adjacent implants in the esthetic zone (Figs 15a–d) (Rodríguez-Ciurana et al. 2009; Levine et al. 2021). Rivara et al. (2020) reported adjacent implants in the pre-molar region suggested that there were no differences between a 2-mm and 3-mm inter-implant distance to clinical, radiographic and esthetic outcomes when using platform-switching implants at 12 months. Therefore, when placing adjacent implants in the anterior region, conical connection with platform-switching should be the first choice. Posteriorly, it is more likely that > 3 -mm inter-implant distance can be achieved, preserving inter-dental bone and papillas with non-PS implants (Fig. 16).

TISSUE LEVEL/BONE LEVEL

One major distinguishing feature between implant macro-designs is tissue level (TL) versus bone level (BL). With TL implants there is a machined collar that moves the micro-gap more than 1.5 mm coronal to the bone crest. Bone level implants are designed to be placed at or below the alveolar crest (Buser et al. 1997; Sasada & Cochran 2017).

Tissue level and platform switched bone level implants with conical connections show similar marginal bone loss (MBL) over time (Vouros et al. 2012; Vianna et al. 2018). Bone level and tissue level studies have shown less abutment loosening with TL than BL implants (Levine et al. 2002; Levine et al.

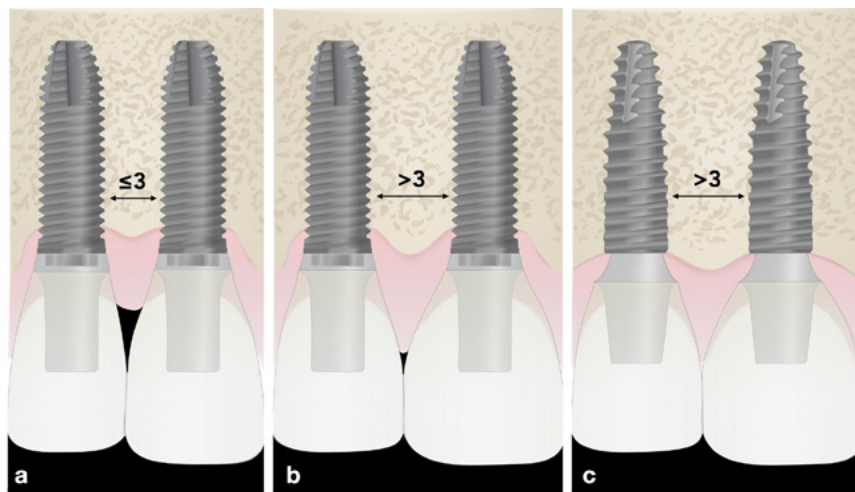


Fig. 14: Adjacent implants in the esthetic zone. a: External hexagon implant connections with platform matching abutments and an inter-implant distance ≤ 3 mm. The saucerization processes were combined, resulting in loss of bone height, and inter-implant papilla, and formation of a black triangle. b: The same implant connection and abutments, but respecting a minimum distance wider than 3 mm, observe the saucerization processes around both implants, separated by a bone crest. c: Conical connections implants with platform-switching abutments, resulting in a minimum bone loss, and presence of inter-implant papilla

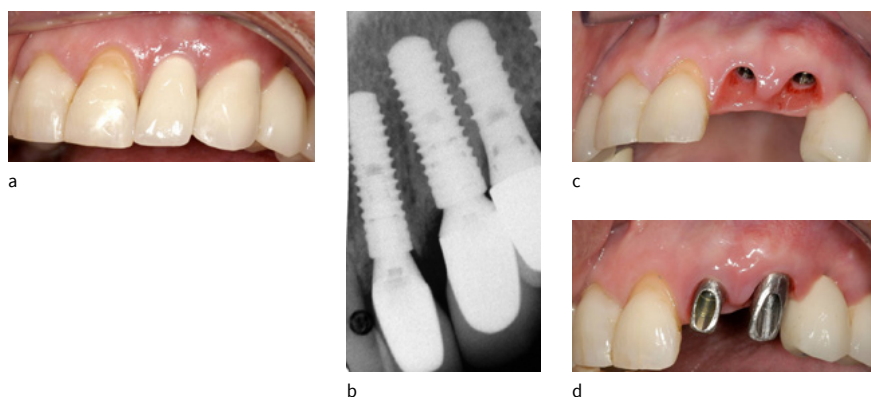


Fig. 15: Adjacent platform-switched implants in the esthetic zone. a: Final restorations 2 years post-op show excellent esthetics and tissue stability with full inter-implant papilla. b: Radiograph shows inter-implant bone level at or coronal to implant shoulders. c: Abutments removed showing excellent tissue health. d: Abutments in place showing restorative design for cemented restorations

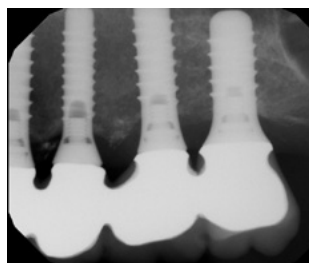


Fig. 16: Well-spaced posterior tissue level implants with inter-implant bony peaks supporting papillas, 23 years post-op

2007). In theory, this is due to the tissue level collar accepting the off-axial forces and distributing them onto a wider surface, relieving the internal connection and the pre-load of the screw.

When planning implant placement in the esthetic zone, bone level implants can be advantageous (Figs 17a–b) because of greater flexibility with prosthetic components and tissue management options. Due to the absence of a machined transmucosal collar, BL implants with platform shifts can be placed at sub-crestal positions, which allows for more control over the soft tissue emergence and esthetics (Linkevicius et al. 2015). Some long-term studies revealed slightly better esthetic outcomes for BL compared to TL implants (Buser et al. 2013; Buser et al. 2014; Zhao et al. 2016; Siebert et al. 2018; Meijndert et al. 2020). This also can be explained because tissue translucency allows the machined collar to show through the mucosa (Figs 18a–b) similar to the way abutment color can affect gingival esthetics (Jung et al. 2007; Jung et al. 2008). With thick, healthy gingiva, TL implants can be restored with excellent esthetics (Figs 19a–c). Both types of implants have shown similar bone stability in the esthetic zone (Chappuis et al. 2016).

At posterior sites, TL implants may be used more frequently since esthetics are generally not critically important (Figs 20a–b). Derks et al. (2016) and Rokn et al. (2017) showed that, in the long-term follow-up, implants with crown restoration margins at a distance > 1.5 mm from the crestal bone showed less peri-implantitis compared to bone level implants, where implants have restorative margins closer to bone. Tissue level implants may have advantages where high stresses are anticipated, such as restorations with a cantilever or high crown-to-implant ratio because of their better force distribution (Chang et al. 2013).

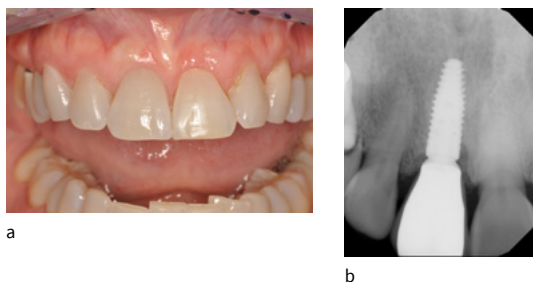


Fig. 17: Right-central incisor replaced with an implant-supported crown on a platform-switched bone level implant in a patient with high esthetic risk. a: Facial view showing maintenance of labial contour and interdental papillas. b: Radiograph showing excellent crestal bone maintenance

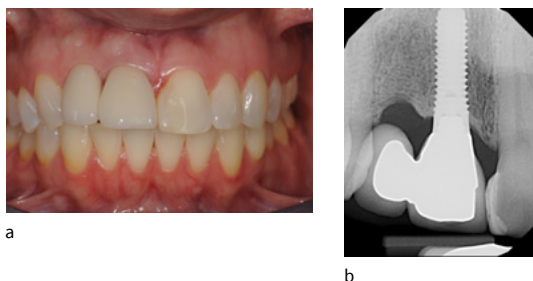


Fig. 18: Right-central and lateral incisors replaced with cantilever bridge supported by a tissue level implant 8 years post-op. a: Facial view showing discoloration and graying of the labial gingiva near the margin. b: Radiograph showing excellent crestal bone maintenance

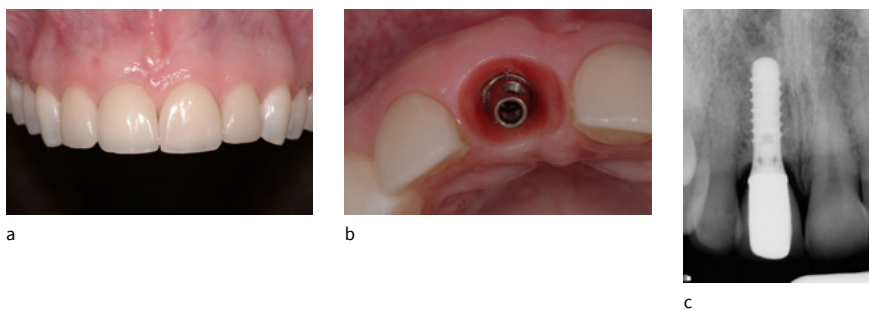


Fig. 19: Right-central incisor replaced with an implant-supported crown on a tissue level implant in a patient with thick tissue and high esthetic demands 4 years post-op. a: Facial view showing maintenance of labial contour and interdental papillas without gingival color change. b: Occlusal view with crown off showing thickness of labial tissue. c: Radiograph showing excellent crestal bone maintenance

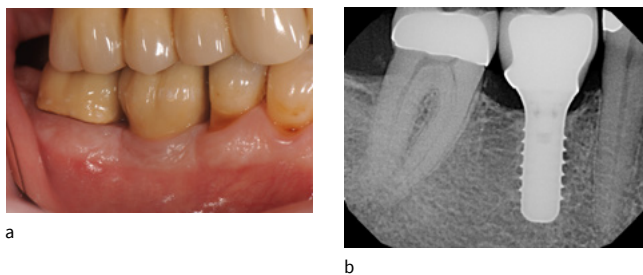


Fig. 20: Mandibular molar replaced with an implant-supported crown at 10 years. a: Facial view showing good esthetics and tissue stability. b: Radiograph showing excellent crestal bone maintenance

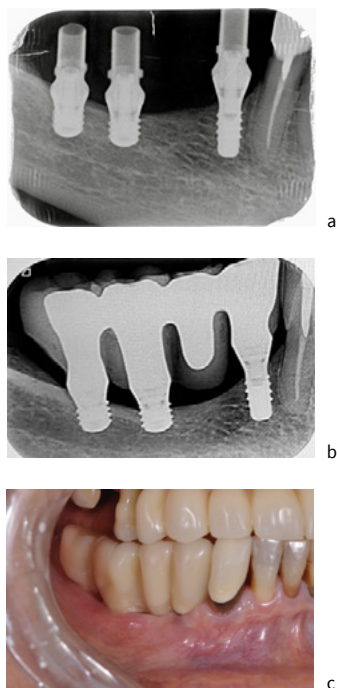


Fig. 21: Posterior fixed partial denture supported by 2 very short and 1 small diameter implants which cannot tolerate saucerization as they could risk losing 50% of their bone support. a: Radiograph taken at the time of provisionalization. b: Radiograph taken 6 years after restoration showing excellent maintenance of crestal bone levels, despite unfavorable crown/implant ratio (>2.5). c: Clinical view showing elongated crowns to fill restorative space

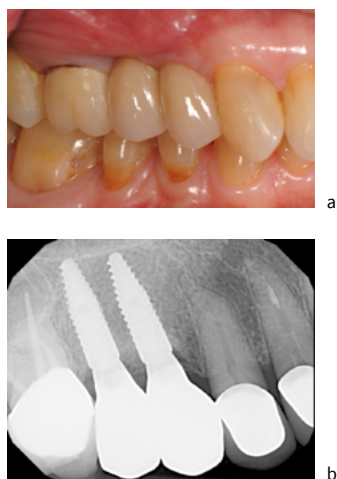


Fig. 22: Adjacent reduced-diameter platform-switched implants ~2mm apart for edentulous space management and restorative planning. a: Clinical view showing good esthetics and contours. b: Radiograph showing good maintenance of crestal bone height

Short implants are often used posteriorly to avoid the mandibular canal and maxillary sinuses. Preserving crestal bone is particularly important with short implants because of their limited length and surface area. They cannot tolerate “saucerization” or loss of 1–2 mm of bone support. Implants designed to preserve crestal bone should be used in these situations (Fig. 21).

Bone level implants are also successful in posterior regions. In certain conditions, such as limited interdental space within crowns or proximity to the maxillary sinus, these implants can be advantageous. The absence of a transmucosal collar allows clinicians to place adjacent implants in reduced spaces (Figs 22a–b). These implants can accept a larger discrepancy in angulation, avoiding important anatomical structures.

The implant shoulder is the area in which the abutment, hard and soft tissue all interface. If a machined surface is placed sub-crestally, bone loss can be expected. Rough surfaces tend to maintain crestal bone height compared to machined surfaces. (Shin et al. 2006; Messias et al. 2019).

CONCLUSIONS AND RECOMMENDATIONS

1. Tapered implants are indicated when interdental space is limited apically, or when alveolar anatomy creates the likelihood of a fenestration.
2. Cylindrical implants are easier to adjust apico-coronal insertion depth compared to tapered implants.
3. Implants with increased thread depth and tapered implants achieve higher insertion torque and RFI measurements, which can facilitate early and immediate loading.
4. Platform-switched implants maintain crestal bone levels better compared to matched connection bone level implants.
5. Conical internal connections reduce micromovement which improves crestal bone maintenance compared to external hex and non-conical connections.
6. In the esthetic zone, bone level implants are generally preferred. When treating a thin phenotype, tissue level implants are contraindicated.
7. In posterior non-esthetic areas, tissue level and bone level implants are equally recommended assuming axial placement and restoration as long as restorative crown margins are 1.5 mm or greater from the bone crest.
8. When planning non-axial placement and restoration, bone level implants are recommended over tissue level implants.

ACKNOWLEDGMENTS

The authors acknowledge no conflicts in writing this review. The authors would like to thank Drs. Robert Vogel and Waldemar Polido for their clinical contributions to this article.

REFERENCES

- Abuhussein, H., Pagni, G., Rebaudi, A. & Wang, H.-L. (2010) The effect of thread pattern upon implant osseointegration. *Clinical Oral Implants Research* **21**: 129–136.
- Albrektsson, T., Branemark, P. I., Hansson, H. A., & Lindstrom, J. (1981). Osseointegrated titanium implants. Requirements for ensuring a long-lasting, direct bone-to-implant anchorage in man. *Acta Orthopaedica Scandinavica* **52**: 155–170.
- Albrektsson, T., Zarb, G., Worthington, P. & Eriksson, A. R. (1986) The long-term efficacy of currently used dental implants: a review and proposed criteria of success. *International Journal of Oral & Maxillofacial Implants* **1**: 11–25.
- Annibali, S., Bignozzi, I., Cristalli, M. P., Graziani, F., La Monaca, G. & Polimeni, A. (2012) Peri-implant marginal bone level: a systematic review and meta-analysis of studies comparing platform switching versus conventionally restored implants. *Journal of Clinical Periodontology* **39**: 1097–1113.
- Araújo, M. G., & Lindhe, J. (2005). Dimensional ridge alterations following tooth extraction. An experimental study in the dog. *Journal of Clinical Periodontology* **32**: 212–218.
- Atieh, M. A., Alsabeeha, N. & Duncan, W. J. (2018) Stability of tapered and parallel-walled dental implants: A systematic review and meta-analysis. *Clinical Implant Dentistry and Related Research* **20**: 634–645.
- Barone, A., Fortunato, A., Deschi, G., Tonelli, P., Toti, P., Marchionni, S. & Covani, U. (2016) The effect of insertion torque on the clinical outcome of single implants: A randomised clinical trial. *Clinical Implant Dentistry and Related Research* **18**: 588–600.
- Benic, G. I., Mokti, M., Chen, C.-J., Weber, H. P., Hämmerle, C. H. & Gallucci, G. O. (2012). Dimensions of buccal bone and mucosa at immediately placed implants after 7 years: a clinical and cone beam computed tomography study. *Clinical Oral Implants Research* **23**: 560–566.
- Berglundh, T. & Lindhe, J. (1996). Dimension of the periimplant mucosa: biological width revisited. *Journal of Clinical Periodontology* **23**: 971–973.
- Buser, D., Chappuis, V., Bornstein, M. M., Wittneben, J. G., Frei, M. & Belser, U. C. (2013). Long-term stability of contour augmentation with early implant placement following single tooth extraction in the esthetic zone: a prospective, cross-sectional study in 41 patients with a 5-to 9-year follow-up. *Journal of Periodontology* **84**: 1517–1527.
- Buser, D., Chappuis, V., Kuchler, U., Bornstein, M. M., Wittneben, J. G., Buser, R., ... & Belser, U. C. (2013). Long-term stability of early implant placement with contour augmentation. *Journal of Dental Research* **92**(12_suppl): 176S–182S.
- Buser, D., Mericske-Stern, R., Pierre Bernard, J. P., Behneke, A., Behneke, N., Hirt, H. P., ... & Lang, N. P. (1997). Long-term evaluation of non-submerged ITI implants. Part 1: 8-year life table analysis of a prospective multi-center study with 2359 implants. *Clinical Oral Implants Research* **8**: 161–172.
- Caricasulo, R., Malchiodi, L., Ghensi, P., Fantozzi, G. & Cucchi, A. (2018) The influence of implant-abutment connection to peri-implant bone loss: A systematic review and meta-analysis. *Clinical Implant Dentistry and Related Research* **20**: 653–664.
- Chang, H. S., Chen, Y. C., Hsieh, Y. D. & Hsu, M. L. (2013) Stress distribution of two commercial dental implant systems: A three-dimensional finite element analysis. *Journal of Dental Sciences* **8**: 261–271.
- Chappuis, V., Bornstein, M. M., Buser, D., & Belser, U. (2016). Influence of implant neck design on facial bone crest dimensions in the esthetic zone analyzed by cone beam CT: A comparative study with a 5-to-9-year follow-up. *Clinical Oral Implants Research* **27**: 1055–1064.
- Chappuis, V., Rahman, L., Buser, R., Janner, S. F. M., Belser, U. C. & Buser, D. (2018) Effectiveness of contour augmentation with guided bone regeneration: 10-year results. *Journal of Dental Research* **97**: 266–274.
- Derks, J., Schaller, D., Håkansson, J., Wennström, J. L., Tomasi, C. & Berglundh, T. (2016). Effectiveness of implant therapy analyzed in a Swedish population: prevalence of peri-implantitis. *Journal of Dental Research* **95**: 43–49.
- El Kholi, K., Ebenezer, S., Wittneben, J.-G., Lazarin, R., Rousson, D. & Buser, D. (2019) Influence of implant macrodesign and insertion connection technology on the accuracy of static computer-assisted implant surgery. *Clinical Implant Dentistry and Related Research* **21**: 1073–1079.
- Esposito, M., Grusovin, M. G., Willings, M., Coulthard, P., & Worthington, H. V. (2007). The effectiveness of immediate, early, and conventional loading of dental implants: a Cochrane systematic review of randomized controlled clinical trials. *International Journal of Oral & Maxillofacial Implants* **22**: 893–904.
- Gallucci, G.O., Hamilton, A., Zhou, W., Buser, D. & Chen, S. (2018). Implant placement and loading protocols in partially edentulous patients: A systematic review. *Clinical Oral Implants Research* **29**: 106–134.
- Gehrke, S. A. & Marin, G. W. (2014) Biomechanical evaluation of dental implants with three different designs: Removal torque and resonance frequency analysis in rabbits. *Annals of Anatomy* **199**: 30–35.
- Gehrke, S. A., da Silva, U. T. & Del Fabbro, M. (2015) Does Implant Design Affect Implant Primary Stability? A Resonance Frequency Analysis-Based Randomized Split-Mouth Clinical Trial. *Journal of Oral Implantology* **41**: e281–e286.
- Geng, J. P., Xu, D. W., Tan, K. B. & Liu, G. R. (2004) Finite element analysis of an osseointegrated stepped screw dental implant. *Journal of Oral Implantology* **30**: 223–233.
- Gultekin, B. A., Gultekin, P., Leblebicioglu, B., Basegmez, C. & Yalcin, S. (2013). Clinical evaluation of marginal bone loss and stability in two types of submerged dental implants. *International Journal of Oral & Maxillofacial Implants* **28**: 815–823.
- Hermann, J. S., Cochran, D. L., Hermann, J. S., Buser, D., Schenk, R. K. & Schoolfield, J. D. (2001b). Biologic Width around one- and two-piece titanium implants: A histometric evaluation of unloaded nonsubmerged and submerged implants in the canine mandible. *Clinical Oral Implants Research* **12**: 559–571.
- Hermann, J. S., Schoolfield, J. D., Schenk, R. K., Buser, D. & Cochran, D. L. (2001a) Influence of the size of the microgap on crestal bone changes around titanium implants. A histometric evaluation of unloaded non-submerged implants in the canine mandible. *Journal of Periodontology* **72**: 1372–1383.

- Jimbo, R., Tovar, N., Anchieta, R. B., Machado, L. S., Marin, C., Teixeira, H. S. & Coelho, P. G. (2014) The combined effect of undersized drilling and implant macrogeometry on bone healing around dental implants: an experimental study. *International Journal of Oral & Maxillofacial Surgery* **43**: 1269–1275.
- Jokstad, A. & Ganeles, J. (2018) Systematic review of clinical and patient-reported outcomes following oral rehabilitation on dental implants with a tapered compared to a non-tapered implant design. *Clinical Oral Implants Research* **29**(Suppl. 16): 41–54.
- Jung, R. E., Al-Nawas, B., Araujo, M., et al. (2018) Group 1 ITI Consensus Report: The influence of implant length and design and medications on clinical and patient-reported outcomes. *Clinical Oral Implants Research* **29**(Suppl. 16): 69–77.
- Jung, R. E., Holderegger, C., Sailer, I., Khraisat, A., Suter, A. & Hammerle, C. H. (2008). The effect of all-ceramic and porcelain-fused-to-metal restorations on marginal peri-implant soft tissue color: a randomized controlled clinical trial. *The International Journal of Periodontics and Restorative Dentistry* **28**: 357–365.
- Jung, R. E., Sailer, I., Hammerle, C. H. F., Attin, T. & Schmidlin, P. (2007). In vitro color changes of soft tissues caused by restorative materials. *International Journal of Periodontics and Restorative Dentistry* **27**: 251.
- Jung, R. E., Zembic, A., Pjetursson, B. E., Zwahlen, M. & Thoma, D. S. (2012) Systematic review of the survival rate and the incidence of biological, technical and esthetic complications of single crowns on implants reported in longitudinal studies with a mean follow-up of 5 years. *Clinical Oral Implants Research* **23**(Suppl. 6): 2–21.
- Kim, Y. K., Lee, J. H., Lee, J. Y., & Yi, Y. J. (2013). A randomized controlled clinical trial of two types of tapered implants on immediate loading in the posterior maxilla and mandible. *International Journal Oral & Maxillofacial Implants*, **28**: 1602–1611.
- Koutouzis, T. (2018) Implant-abutment connection as contributing factor to peri-implant diseases. *Periodontology 2000* **81**: 152–166.
- Lazzara, R. & Porter, S. (2006) Platform-switching: a new concept in implant dentistry for controlling post restorative crestal bone levels. *International Journal of Periodontics and Restorative Dentistry* **26**: 9–17.
- Levine, R. A., Clem, D., Beagle, J., Ganeles, J., Johnson, P., Solnit, G. & Keller, G. W. (2002) Multi-center retrospective analysis of the solid-screw ITI implant for posterior single-tooth replacements. *International Journal of Oral & Maxillofacial Implants* **17**: 550–556.
- Levine, R. A., Ganeles J., Gonzaga L., Kan J. Y., Randel H., Evans C. D. & Chen S. T. (2017) 10 Keys for Successful Esthetic-Zone Single Immediate Implants. *Compendium for Continuing Dental Education* **38**: 248–261.
- Levine, R. A., Ganeles, J., Jaffin, R. A., Clem III, D. S., Beagle, J. R., & Keller, G. W. (2007). Multicenter Retrospective Analysis of Wide-Neck Dental Implants for Single Molar Replacement. *International Journal of Oral & Maxillofacial Implants* **22**: 736–742.
- Levine, R. A., Ganeles, J., Wang, P., Makrauer, Z. A., Araujo, M. G., Dias, D. R., Gonzaga, L., Evans, C. & Chen, S. (2021) Application of the 10 Keys for Replacement of Multiple Teeth in the Esthetic Zone. *The Compendium of Continuing Education in Dentistry* (accepted for publication October 2020). Publication date: June 2021.
- Linkevicius, T., Puisys, A., Steigmann, M., Vindasiute, E. & Linkeviciene, L. (2015). Influence of vertical soft tissue thickness on crestal bone changes around implants with platform switching: a comparative clinical study. *Clinical Implant Dentistry and Related Research* **17**: 1228–1236.
- Linkevicius, T., Vindasiute, E., Puisys, A., Linkeviciene, L., Maslova, N., & Puriene, A. (2013). The influence of the cementation margin position on the amount of undetected cement. A prospective clinical study. *Clinical Oral Implants Research* **24**: 71–76.
- Martinez, H., Davarpanah, M., Missika, P., Celletti, R. & Lazzara, R. (2001) Optimal implant stabilization in low density bone. *Clinical Oral Implants Research* **12**: 423–432.
- McCullough, J. J. & Klokkevold, P. R. (2017) The effect of implant macro-thread design on implant stability in the early post-operative period: a randomized controlled pilot study. *Clinical Oral Implants Research* **28**: 1218–1226.
- Meijndert, C. M., Raghoobar, G. M., Santing, H. J., Vissink, A. & Meijer, H. J. (2020). Performance of bone-level implants with conical connections in the anterior maxilla: A 5-year prospective cohort study. *Clinical Oral Implants Research* **31**: 173–180.
- Messias, A., Nicolau, P. & Guerra, F. (2019). Titanium dental implants with different collar design and surface modifications: A systematic review on survival rates and marginal bone levels. *Clinical Oral Implants Research* **30**: 20–48.
- Monje, A., & Pommer, B. (2015). The Concept of Platform Switching to Preserve Peri-implant Bone Level: Assessment of Methodologic Quality of Systematic Reviews. *International Journal of Oral & Maxillofacial Implants* **30**: 1084–1092.
- Monje, A., Chappuis, V., Gil, F. M., Muñoz, F., Wang, H. L., Urban, I. A. & Buser, D. (2019). The Critical Peri-implant Buccal Bone Wall Thickness Revisited: An Experimental Study in the Beagle Dog. *The International Journal of Oral & Maxillofacial Implants* **34**: 1328–1336.
- Morton, D., Gallucci, G., Lin, W., et al. (2018) Group 2 ITI Consensus Report: Prosthodontics and implant dentistry. *Clinical Oral Implants Research* **29**(Suppl. 16): 215–223.
- Nicolau P, Korostoff J, Ganeles, J, et al. (2013) Immediate and early loading of chemically modified implants in the posterior jaws: 3-year results from a prospective randomized multicenter study. *Clinical Oral Implants Research* **15**: 600–612.
- Ramanauskaite, A., Rocuzzo, A. & Schwarz, F. (2018). A systematic review on the influence of the horizontal distance between two adjacent implants inserted in the anterior maxilla on the inter-implant mucosa fill. *Clinical Oral Implants Research* **29**: 62–70.
- Rivara, F., Macaluso, G. M., Toffoli, A., Calciolari, E., Goldoni, M. & Lumetti, S. (2020) The effect of a 2-mm inter-implant distance on esthetic outcomes in immediately non-occlusally loaded platform shifted implants in healed ridges: 12-month results of a randomized clinical trial. *Clinical Implant Dentistry and Related Research*, **22**: 486–496.
- Rodríguez-Ciurana, X., Vela-Nebot, X., Segalà-Torres, M., Calvo-Guirado, J. L., Cambra, J., Méndez-Blanco, V. & Tarnow, D. P. (2009). The Effect of Interimplant Distance on the Height of the Inter-implant Bone Crest When Using Platform-Switched Implants. *International Journal of Periodontics & Restorative Dentistry* **29**: 140–151.

- Rokn, A., Aslroosta, H., Akbari, S., Najafi, H., Zayeri, F. & Hashemi, K. (2017). Prevalence of peri-implantitis in patients not participating in well-designed supportive periodontal treatments: a cross-sectional study. *Clinical Oral Implants Research* **28**: 314–319.
- Sanz, M., Lindhe, J., Alcaraz, J., Sanz-Sanchez, I. & Cecchinato, D. (2017). The effect of placing a bone replacement graft in the gap at immediately placed implants: a randomized clinical trial. *Clinical Oral Implants Research* **28**: 902–910.
- Sasada, Y. & Cochran, D. L. (2017). Implant-Abutment Connections: A Review of Biologic Consequences and Peri-implantitis Implications. *International Journal of Oral & Maxillofacial Implants* **32**: 1296–1307.
- Shin, Y. K., Han, C. H., Heo, S. J., Kim, S. & Chun, H. J. (2006) Radiographic evaluation of marincal bone level around implants with different neck designs after 1 year. *International Journal of Oral & Maxillofacial Implants* **21**: 789–794.
- Siebert, C., Rieder, D., Eggert, J., Wichmann, M. G. & Heckmann, S. M. (2018). Long-Term Esthetic Outcome of Tissue-Level and Bone-Level Implants in the Anterior Maxilla. *International Journal of Oral & Maxillofacial Implants* **33**: 905–912.
- Strietzel, F. P., Neumann, K. & Hertel, M. (2015). Impact of platform switching on marginal peri-implant bone-level changes. A systematic review and meta-analysis. *Clinical Oral Implants Research* **26**: 342–358.
- Tabassum A., Walboomers, X.F., Meijer G.J., et al. (2011). Biological limits of the undersized surgical technique: A study in goats. *Clinical Oral Implants Research* **22**: 129–134.
- Tarnow, D., Cho, S. C. & Wallace, S. S. (2000). The effect of inter-implant distance on the height of inter-implant bone crest. *Journal of Periodontology* **71**: 546–549.
- Terheyden, H., Lang, N. P., Bierbaum, S. & Stadlinger, B. (2012) Osseointegration – communication of cells. *Clinical Oral Implants Research* **23**: 1127–1135.
- Toyoshima, T., Tanaka, H., Ayukawa, Y., Howashi, M., Masuzaki, T., Kiyosue, T. & Koyano, K. Primary Stability of a Hybrid Implant Compared with Tapered and Cylindrical Implants in an Ex Vivo Model. *Clinical Implant Dentistry and Related Research* **17**: 950–956.
- Vianna, T.T., Taiete, T., Casarin, R.C., Giorgi, M.C., Aguiar, F.H.B., Silvério, K.G., ... & Casati, M. Z. (2018). Evaluation of peri-implant marginal tissues around tissue-level and bone-level implants in patients with a history of chronic periodontitis. *Journal of Clinical Periodontology* **45**: 1255–1265.
- Vouros, I. D., Kalpidis, C. D., Horvath, A., Petrie, A. & Donos, N. (2012). Systematic assessment of clinical outcomes in bone-level and tissue-level endosseous dental implants. *International Journal of Oral & Maxillofacial Implants* **27**: 1359–1374.
- Waechter, J., de Matos Madruga, M., do Carmo Filho, L. C., Manzolli Leite, F. R., Ribeiro Schinestsck, A. & Faot, F. (2017) Comparison between tapered and cylindrical implants in the posterior regions of the mandible: A prospective, randomized split-mouth clinical trial focusing on implant stability changes during early healing. *Clinical Implant Dentistry and Related Research*, **19**: 733–741.
- Zhao, X., Qiao, S. C., Shi, J. Y., Uemura, N., Arai, K. & Lai, H.C. (2016). Evaluation of the clinical and aesthetic outcomes of Straumann® Standard Plus implants supported single crowns placed in non-augmented healed sites in the anterior maxilla: a 5–8 years retrospective study. *Clinical Oral Implants Research* **27**: 106–112.
- Zipprich, H., Weigl, P., Ratka, C., Lange, B. & Lauer, H. C. (2018). The micromechanical behavior of implant-abutment connections under a dynamic load protocol. *Clinical Implant Dentistry and Related Research* **20**: 814–823.